



**PRESENTING CLINICAL SIGNS**

**DATE** History: Grade 3/6 murmur. Previously diagnosed with degenerative valve disease. History of CaOx bladder stones.

8/22/22

**ECHOCARDIOGRAPHIC FINDINGS**

2D, M-mode, and Doppler study.

**PERFORMED BY:**

Kelly Vazquez

Left atrial size is normal. The mitral valve leaflets are thickened, and a mild to moderate jet of eccentric mitral regurgitation is present. Left ventricular dimensions are normal. Left ventricular systolic function is normal. The aorta and aortic valve are normal. Right atrial and right ventricular dimensions are normal. The tricuspid valve appears normal, though trace tricuspid regurgitation is present. The pulmonary artery and pulmonic valve are normal. No shunting lesions are visualized. No heartworms are visualized. No pericardial effusion or cardiac masses are seen.

**INTERPRETED BY**

Keith Blass, DVM,  
MS, DACVIM  
(Cardiology)

LA - 32.9 mm  
LVIDd - 31.6 mm  
LVIDs - 18.4 mm  
FS - 41.8%  
RA - 22.2 mm  
LVOT - 1.31 m/s  
RVOT - 1.04 m/s

**PATIENT**

Beau Puleo

**ASSESSMENT/RECOMMENDATIONS**

Degenerative mitral valve disease

**SPECIES**

Canine

This examination demonstrates mild to moderate regurgitation of blood across Beau's mitral valve resulting from his previously diagnosed degenerative valve disease. The hemodynamic effects of the regurgitation appear to be fairly mild, as Beau does not have secondary dilation of either of his left heart chambers, and his left ventricular systolic function is normal. As such, Beau's mitral valve disease appears to be well-compensated, and his current risk for the development of clinical signs secondary to it, such as coughing, exercise intolerance, syncope, and labored breathing, appears to be relatively low.

**BREED**

Cavapoo

**SEX**

No therapy is recommended at this stage of Beau's mitral valve disease.

**MN**

A recheck echocardiogram is recommended in 6 months to monitor for disease progression.

**AGE**

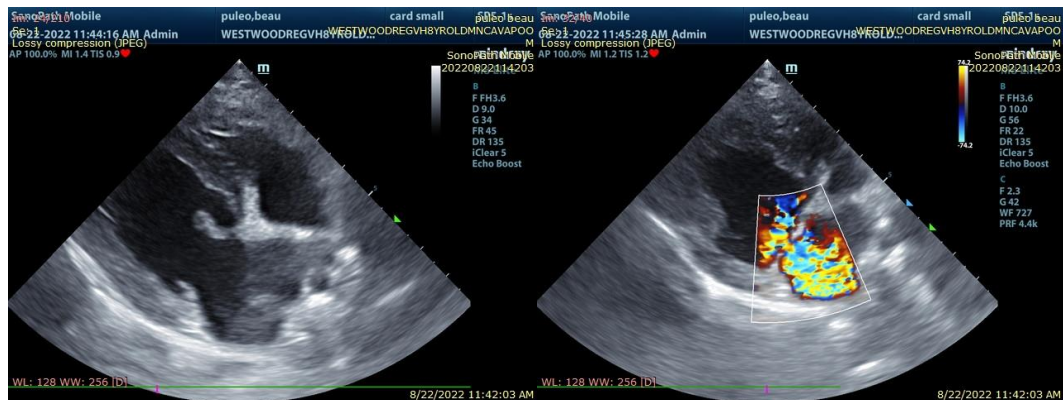
8 y

**WEIGHT**

25.5 lb

**HOSPITAL NAME**

Westwood Regional  
VH



**REFERRING VET**

Dr. Hartwick

The information and recommendations provided are based on the images presented by the referring veterinarian. No evaluation can be communicated regarding pathology that was not



visible in the image/video clips provided.

**DATE**

8/22/22

Thank you for this referral. If the clinical or image interpretation does not parallel your findings or if I can be of any further assistance please contact me.

**PERFORMED BY:**

**Keith Blass, DVM, MS, DACVIM (Cardiology)**  
KeithBlass@gmail.com  
631-804-5754

Kelly Vazquez

**INTERPRETED BY**

Keith Blass, DVM,  
MS, DACVIM  
(Cardiology)

**PATIENT**

Beau Puleo

**SPECIES**

Canine

**BREED**

Cavapoo

**SEX**

MN

**AGE**

8 y

**WEIGHT**

25.5 lb

**HOSPITAL NAME**

Westwood Regional  
VH

**REFERRING VET**

Dr. Hartwick